



**PATIENT**

Misty Lansberry

**SPECIES**

Feline

**BREED**

DSH

**SEX**

Female Spayed

**AGE**

7.20.06

**WEIGHT**

10.19lbs

**INTERPRETED BY**

Maggie Machen Lamy,  
DVM, DACVIM  
(Cardiology)

**HOSPITAL NAME**

Banfield Timonium

**REFERRING VET**

Dr. Borrison

**INVOICE**

26554

**DATE**

9.26.22

**PRESENTING CLINICAL SIGNS**

History: Recheck echo. History of coughing for about 1 month. History of heart murmur.

-Pertinent abnormal PE/Chem/CBC/UA Results: CBC/Chemistry NSF, Electrolytes NSF, T4 NSF, Cardio ProBNP normal on 9/7/22.

-Current medications: None listed.

-Sedation used: Not required to complete full diagnostic ultrasound.

-Pertinent previous ultrasound results (11/2019 MML): Normal remodeling unknown murmur.

-STAT: Not requested.

-Imaging performed by: Stephanie Warga RDCS, RVT.

**ECHOCARDIOGRAM FINDINGS**

2D, m-mode, color flow and doppler imaging is available. The left ventricular wall is normal in dimension with regions of irregularity. There is a diffusely hyperechoic endocardium consistent with fibrosis. The papillary muscles are remodeled. The left atrium is normal in size. The right atrium is normal. No TR. The right ventricle appears normal. The mitral valve is normal in structure and mobility. Blood flow through the RVOT is normal in velocity. LVOT flow is normal on color flow. No obvious SAM or LVOTO on color or 2D. No obvious cause for the murmur is identified. No pleural or pericardial effusion seen. No obvious cardiac tumors.

**CARDIAC CHART**

FELINE CARDIAC PARAMETERS	BODY WEIGHT (kg)	HR (BPM)	IVSd (cm) (Moise, Pipers)	LVIDd (cm) (Moise, Pipers)	LWVd (cm) (Moise, Pipers)	FS (%)	EF (%)
NORMAL PARAMETER	-----	150-240	3.5-0.55	<2 (mean 1.5)	3.5-0.55	35-67	80-100
PATIENT	4.6	NM	0.44	1.3	0.43	68	96
FELINE CARDIAC PARAMETERS	LA/AO (Boon)	LA/AO HEART BASE (Swe) (Abbott)	LA 2D short axis Base view (cm) (Abbott)		LVOT VEL (m/s)	RVOT VEL (m/s)	E max (m/s)
NORMAL	<1.5	<1.3	<1.2		<1.6	<1.3	<0.9
PATIENT	NM	1.2	1.15		1.0	1.0	NM

Adapted from June Boon, Veterinary Echocardiography, 1998  
Abbott J & MacLean H JVIM 2006;20: 111-119, Moise et al. Am J Vet Res 47:1476, 1986. Pipers et al. Am J Vet Res 40:882, 1979.

### INTERPRETATION OF THE FINDINGS & FURTHER RECOMMENDATIONS

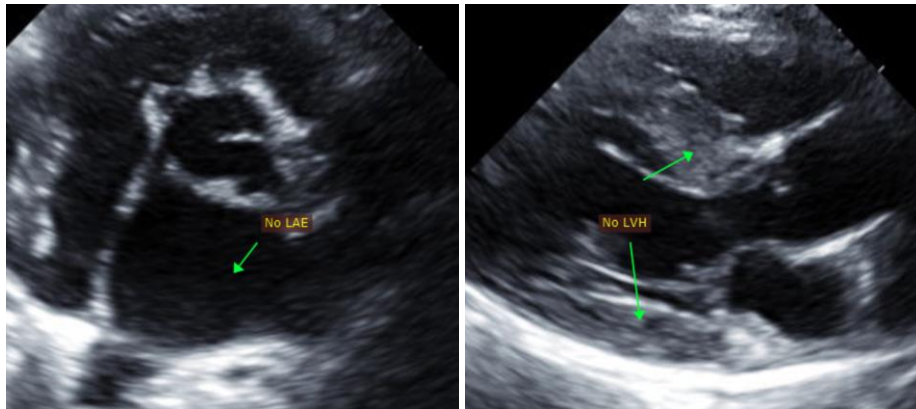
Persistently normal cardiac structure and function is identified in this study. No LV hypertrophy or LA enlargement have developed. The murmur remains benign in origin without an obvious cause.

Given these findings, no medications are indicated at this time. The cough is non-cardiac in origin, and primary respiratory issues should be considered.

No cardiac contraindication for general anesthesia or steroid therapy. That being said, even normal older cats are predisposed to fluid retention/overload with steroid use and careful monitoring is advised if used. Monitor at home for any change in RR/RE or signs of a blood clot event (paralysis/lameness neurologic change, etc.).

Recommend recheck assessment in 1 year to reassess murmur origin, and screen for development of disease that the pre-existing murmur may mask, sooner if clinical signs arise.

### IMAGES



**The information and recommendations provided are based on the images presented by the referring veterinarian. No evaluation can be communicated regarding pathology that was not visible in the image/video clips provided.**

Thank you for this referral. This report was generated using transcription software, and minor dictation errors may be present. If the clinical or image interpretation does not parallel your findings or if I can be of any further assistance, please contact me.

**Maggie Machen Lamy, DVM**  
**Diplomate of the American College of Veterinary Internal Medicine (Cardiology)**  
**info@sonopath.com**